



Management of epispadias

Richard W. Grady, MD*, Michael E. Mitchell, MD

*Section of Pediatric Urology, Children's Hospital & Regional Medical Center,
The University of Washington Medical Center, 4800 Sandpoint Way NE, Seattle, WA 98105, USA*

Although epispadias is considered to be the least severe defect of the exstrophy–epispadias complex, the treatment of this anomaly is far from trivial. Epispadias does not involve the body of the bladder or the hindgut but does affect the urethra and can affect the bladder neck. As a consequence, it presents with a spectrum of severity that can affect urinary continence if the epispadias anomaly is proximal enough to affect the urinary sphincter mechanism.

Anatomic features

Features in the male patient

The defect in epispadias involves an absence of the dorsal aspect of the urethra and overlying skin. This defect extends to the bladder neck in the more severely affected proximal cases (Fig. 1). The penis is deflected dorsally and may have true intrinsic dorsal chordee. The corpora cavernosa are splayed laterally due to their attachment to the separated pubic bones. Because of the pubic diastasis associated with epispadias the penis appears variably foreshortened. Magnetic resonance imaging (MRI) evaluation of the penile length of adult male exstrophy and epispadias patients also reveals that the total corporal length is significantly shorter than in a control population. This corporal shortening apparently results from a foreshortened anterior segment (distal to the pelvic attachment). The posterior corporal segment is unaffected [1].

The combination of the short urethral plate and dorsal chordee also creates the appearance of the glans penis lying in close approximation to the prostatic utricle. The ejaculatory ducts empty

at the verumontanum, which is exposed on the urethral plate. The vas and ejaculatory ducts are typically unaffected in male epispadias patients unless they are iatrogenically damaged. Normally, the nerves travel the dorsal aspect of the penis after they traverse the posterolateral aspects of the prostate and the membranous urethra [1]. In the male patient with epispadias, however, the sensory nerves to the glans are paired and located on the lateral aspects of the corporal bodies lateral to the urethral plate. This has obvious implications for later surgical procedures.

The prostate is also incompletely formed in the setting of proximal epispadias [2,3]. The scrotum is not typically involved, although some patients with epispadias have an increased distance between the base of the penile shaft and the scrotum and broadening of the scrotum dependent on the degree of diastasis.

Because of the underlying bladder neck anomalies, male patients with proximal epispadias may have impaired fertility or be completely incontinent. Retrograde ejaculation will occur if the bladder neck does not close completely during emission following reconstruction [4–6].

Features in the female patient

The female patient with epispadias has characteristic anatomic features (Fig. 2). The dorsal aspect of the urethra is absent and the urinary sphincter mechanism is invariably involved. In affected girls the clitoris is bifid, the perineal body is broadened, and the vagina is anterior to its orthotopic position. The mons pubis is absent. In association with a bifid clitoris, the anterior labia are laterally displaced, although they fuse in the midline posteriorly. The vagina and the introitus are displaced anteriorly from their usual positions. The introitus is tilted cephalad. The

* Corresponding author.

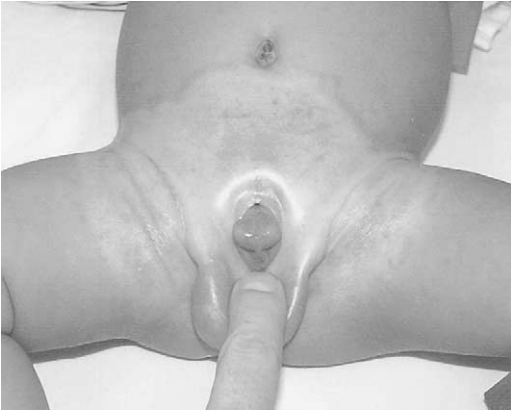

Fig. 1. Four-month-old boy with penopubic epispadias. The bladder neck is exposed at the dorsal base of the penis. Note the skin discoloration secondary to chronic urine contact dermatitis.

vaginal opening may be stenotic in these patients, but the authors have not found this to be a characteristic *de novo* feature. Vaginal stenosis can result as a complication of surgical intervention, however. Internal genital structures (uterus, cervix, fallopian tubes, and ovaries) are usually unaffected, although the cervical os often enters the superior wall of the vagina. Uterine prolapse due to deficient pelvic floor support can occur in older patients and poses particular problems with pregnancy [7]. Early primary reconstruction may decrease this risk. Uterine suspension procedures such as sacrocolpopexy can be employed in these situations as well.

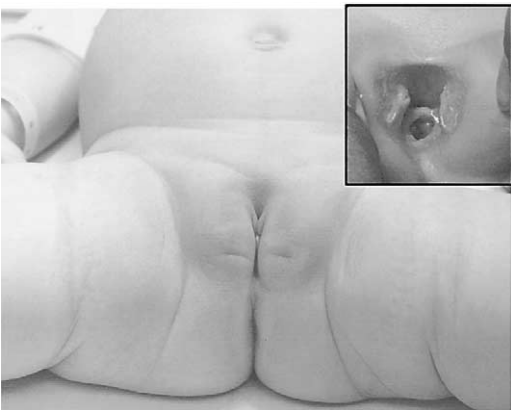


Fig. 2. Three-month-old girl with epispadias. Inset close-up demonstrates bifid clitoris and visible bladder neck at the urethral meatus.

Urinary continence

For boys with penopubic epispadias and girls with epispadias, the bladder neck is invariably involved; it is often wide and incompetent. This involvement directly affects the continence mechanism of these patients and impacts the ability to achieve urinary continence. In untreated boys with epispadias continence is possible if the epispadias is located distally and the bladder neck is not involved. In girls, however, continence is invariably affected to some degree because the urethral and bladder neck ectasia are invariably involved in female epispadias. Because of the shared features with bladder exstrophy, clinicians consider epispadias as part of a spectrum of the exstrophy/epispadias complex. The authors believe that penopubic epispadias in the boy and epispadias in the girl should be repaired completely with a complete primary repair technique at birth, similar to classic exstrophy, to maximize the potential for urinary continence.

Epispadias repair

Male epispadias repair

The ideal approach to male epispadias repair should return the genitourinary anatomy to its normal location and configuration. This will involve the following goals:

- Correction of dorsal chordee
- Creation of a straight urethra to allow easy negotiation during catheterization or cystoscopy
- Satisfactory cosmesis
- Minimal complications, especially regarding urethrocutaneous fistulas
- Maintenance of erectile function
- Creation of urinary continence (penopubic epispadias)

Most currently used repairs are based on the unique blood supply of each corpora, the glans halves and the bladder neck and urethra. Multiple operations have been devised in attempts to achieve these goals. Two procedures in particular deserve discussion because they have proven to be the most successful and because they incorporate an anatomic approach to epispadias repair. These methods are the Cantwell–Ransley technique and the complete penile disassembly (Mitchell) technique. Unlike surgeons before him, Cantwell's efforts to correct epispadias at the turn of the

twentieth century focused on reconstituting the anatomic defect toward normal [8]. The complete penile disassembly technique represents a philosophic extension of Cantwell's approach that maximizes the surgeon's ability to move the urethra, bladder, and bladder neck posteriorly into an anatomically normal location. Both employ dissection of the corporal bodies and transposition of the urethral plate to the ventral aspect of the penis. Lack of length of the urethra may result in hypospadias with either of these techniques. These complications can be corrected later in a variety of ways using operations described for hypospadias repair.

The complete penile disassembly technique allows the bladder neck and urethra to be placed into a more anatomic position in the pelvis. As a result, this technique can effectively correct urinary incontinence as well as the penile abnormalities associated with epispadias with one operation [9]. In contrast, the Cantwell–Ransley technique limits anatomic reconstitution because the urethra is not dissected from the corporal bodies. As a result, patients who undergo a modified Cantwell–Ransley epispadias repair for proximal epispadias typically require another operation specifically targeted at bladder neck reconstruction to achieve urinary continence.

Operative approach to epispadias

Epispadias repair can be challenging. The modified Cantwell–Ransley and complete penile disassembly procedures are described below. Both types of repair can be employed as salvage procedures for patients who have undergone previous operations for epispadias.

Modified Cantwell–Ransley repair

Cantwell first described mobilization and ventral movement of the urethra for epispadias repair at the turn of the twentieth century [8]. Ransley subsequently successfully modified this technique [10]. The modified Cantwell–Ransley repair has been widely used ever since.

Initially, a traction suture is placed into the glans penis. A marking pen is then used to outline the incisions for a reverse meatal advancement and glanuloplasty (MAGPI) or Ipgam procedure at the distal urethral plate. This advances the urethral meatus onto the glans. Skin incisions are then made on the lateral edges of the urethral plate and around the epispadic meatus. This plate

is dissected from the corporal bodies up to the level of the glans distally and to the prostatic urethra proximally. Lateral flaps or wings should be developed in the glans penis as well. The corporal bodies are then separated from each other, allowing them to rotate medially. The urethra is then tubularized over a 6 or 8 French urethral catheter, typically using running absorbable suture. The corporal bodies are rotated over the urethra and re-approximated using absorbable sutures in an interrupted fashion. Caverosotomies may be performed prior to re-approximating the corporal bodies to help correct persistent chordee. These are performed at the point of maximal angulation. Neurovascular bundles may require mobilization to avoid injury if caverosotomies are performed. The glans wings are then closed over the urethra dorsally using interrupted absorbable sutures. Penile shaft skin can be trimmed and tailored to cover the penis. Z-plasties at the level of the pubis may decrease the chance of a dorsal retractile scar at the base of the penis.

Complete penile disassembly (CPD) technique

Bagli and Mitchell first reported results using this technique in 1996 [11]. Complete penile disassembly offers several advantages compared to the modified Cantwell–Ransley technique. The planes of dissection extend anatomically to the bladder neck. This facilitates its use with bladder neck reconstruction. Complete mobilization of the urethral wedge from the corporal bodies by disassembly also creates a more normal appearance of the penis by allowing ventral placement of the urethra. This technique is based on the unique anatomy of the epispadias. The blood supply of each hemiglans is dependent on the *paired* unique dorsal complex found lateral to the urethral plate on the lateral aspect of the corpora. Because the corpora are separated there is little or no crossed blood supply, and the primary circulation of each corpora cavernosa is based on the central artery. Similarly, the urethral plate and spongiosa have their unique blood supplies and are innervated from the proximal urethra (not the distal urethra). The corpora cavernosa with hemiglans can therefore be separated completely from each other and from the spongiosa and urethra complex without potential to damage ultimate function. This disassembly maximizes the potential for anatomic reconstruction. It is important to note that the dorsal complex is *not* dissected from the corpora cavernosal bodies.

Techniques

Initial dissection

To aid in dissection, traction sutures are placed into each hemiglans of the penis. The sutures are placed at the beginning of the operation and are initially oriented *transversely* in the hemiglans (Fig. 3). Following dissection of the corporal bodies and the urethral wedge (urethral plate plus underlying corpora spongiosa) from each other, the sutures will rotate to a parallel vertical orientation as the corporal bodies rotate medially. The authors also use fine-tip tungsten electrocautery (Colorado[®]) tip during this dissection.

The authors begin the penile dissection along the *ventral aspect* of the penis as a circumcising incision. This step precedes dissection of the urethral wedge from the corporal bodies because it is easier to identify Buck's fascia ventrally. The initial plane of dissection occurs just above Buck's fascia. Buck's fascia stops at the corpora spongiosum during the dissection. As the dissection progresses medially, the plane will shift from above the Buck's fascia to above the tunica albuginea on the ventromedial aspect of each corporal body.

The authors routinely color the urethral wedge and epispadic urethra to differentiate urothelium from squamous epithelium. Injection of the surrounding tissues with 0.25% lidocaine; 1:200,000 μ M epinephrine also improves hemostasis, which assists the dissection. The margins of the dorsal urethra are usually obvious. The urethral wedge (urethra and underlying corpora spon-

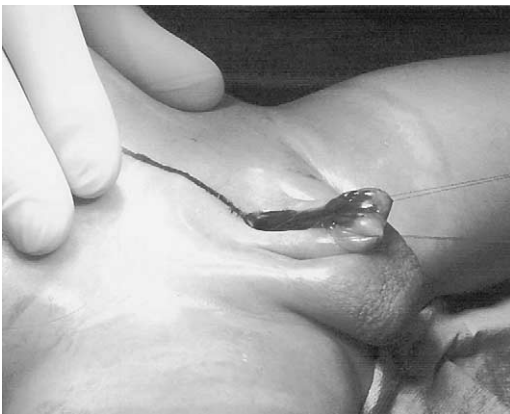

Fig. 3. Glans traction sutures placed into each hemiglans in a transverse orientation. The urethra and bladder neck are shaded to demonstrate the area of dissection.

giosa) is dissected from the dorsomedial aspect of the corpora cavernosa on the tunica albuginea, preserving all of the spongiosa (a triangular wedge of tissue; Fig. 4). The spongiosa will be tubularized later.

Careful lateral dissection of the penile shaft skin and dartos fascia from the corporal bodies is performed above Buck's fascia since the neurovascular bundles are located laterally on the corpora within Buck's fascia [1].

Penile disassembly

To perform the proximal dissection of the urethra and bladder neck from the corporal bodies, the penis is disassembled into three components—the right and left corporal bodies with their respective hemiglans and the urethral wedge (urothelium with underlying corpora spongiosa). This is done primarily to provide exposure of the intersymphyseal band (an anterior condensation of the pelvic diaphragm) and to allow adequate exposure for proximal dissection (Fig. 5). It is easiest to initiate proximally and ventrally. The plane of dissection should be carried out at the level of the tunica albuginea on the corpora. After a plane is established between the urethral wedge and the corporal bodies this dissection is carried distally to separate the three components from each other. This maximizes the degree of freedom for the best repair. The corporal bodies might be completely separated from each other since they exist on separate blood supplies (Fig. 6). It is important to keep the underlying corpora spongiosa with the urethra; the blood supply to the urethra is based on the spongiosal tissue, which should appear wedge-shaped after its dissection from the adjacent corpora cavernosa. This urethral/corporal spongiosal component will later be tubularized and placed ventral to the corporal bodies. Para-exstrophy skin flaps *cannot* be used with this technique and should *never* be used because this maneuver will de-vascularize the distal urethra. The bladder and urethra are moved posteriorly in the pelvis as a unit. In some cases a patient will be left with a hypospadias because of the shortness of the urethra. This will require later surgical reconstruction.

Proximal dissection

Proximal dissection of the urethral wedge from the corporal bodies is critical to the posterior placement of the bladder neck and proximal urethra. Deep incision of the intersymphyseal liga-

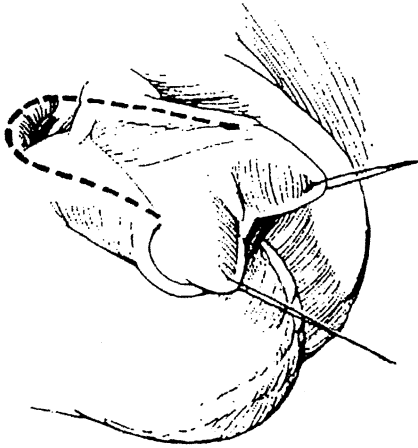
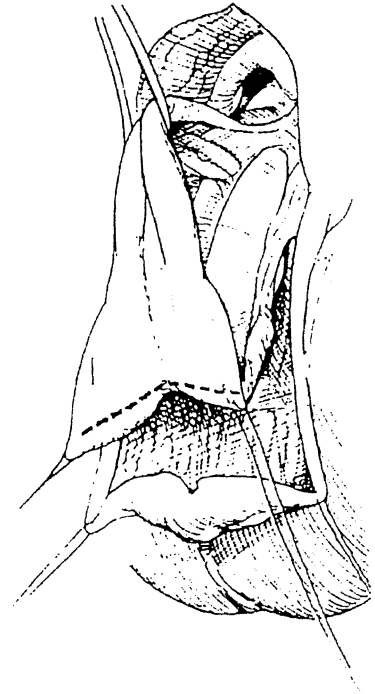

Fig. 4. Plane of dissection between the urethral wedge of tissue and the corpora cavernosa. Note that the initial ventral dissection has already been performed.



ments posterior and lateral to each side of the urethral wedge is absolutely necessary to allow the bladder to achieve a posterior position in the pelvis (Fig. 7). Failure to adequately dissect the bladder

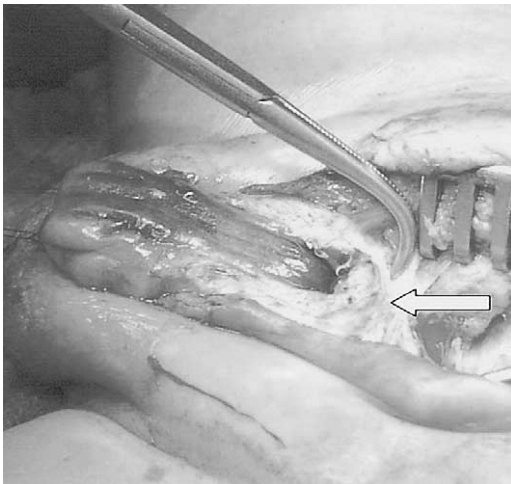


Fig. 5. Lateral plane of dissection reveals the inter-symphyseal band (an anterior condensation of the pelvic diaphragm). This band must be deeply incised to allow the bladder neck and urethra to be placed posteriorly in the pelvis.

and urethral wedge from these surrounding structures will create anterior tension along the urethral plate and prevent posterior movement of the bladder in the pelvis. As the urethral wedge dissection is carried proximally to the bladder neck, take care not to enter the corpora spongiosa at the bulbous urethra. This plane of dissection is usually more superficial than it appears to be at first.

Primary closure

Once the bladder and urethral wedge are adequately dissected the majority of the procedure is completed, and the closure is straightforward and anatomic. Prior to performing the urethral closure, the authors place a suprapubic tube and bring it out through the umbilicus. The authors tubularize the urethra using a two-layer running closure with monofilament and Vicryl® sutures as well (Fig. 8). To reconstitute normal anatomic relationships the tubularized urethra is positioned ventral to the corpora cavernosa. As previously noted, the corporal bodies will rotate medially (Fig. 9). The previously lateral margins of the Buck's fascia of each corpora cavernosa can then be approximated in the midline as a result of this medial rotation. This rotation will

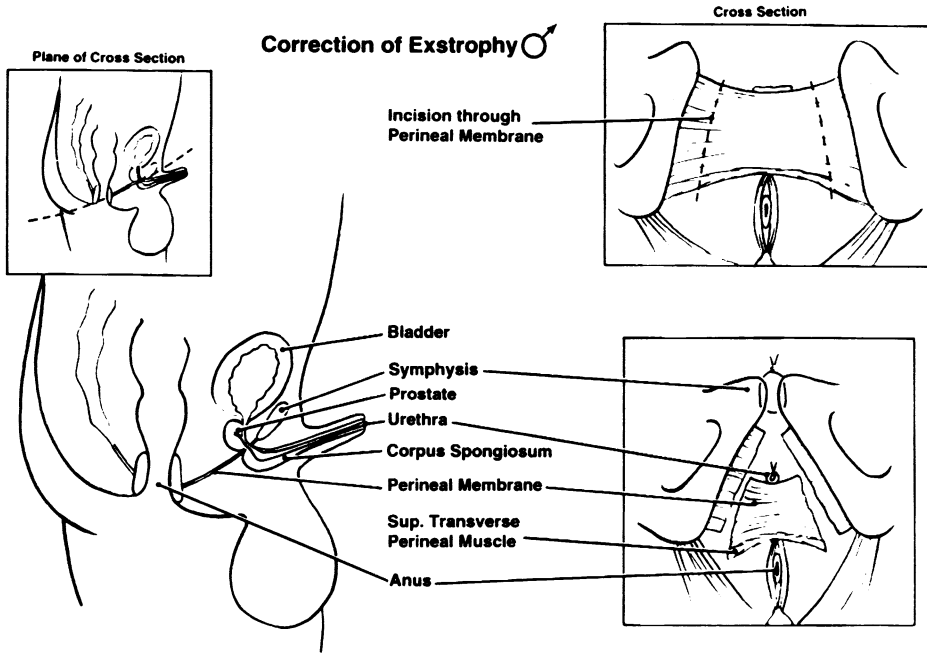


Fig. 6. Cross-sectional view demonstrating the extent of dissection with the complete penile disassembly and primary repair technique in a male with exstrophy. The limit of posterior dissection for penopubic epispadias is the same as it is in exstrophy—the muscular pelvic floor.

assist in correcting dorsal deflection, which can be readily appreciated by observing the newly assumed vertical lie of the previously horizontally placed glans traction sutures.

The authors re-approximate the pubic symphysis using two 0.0 polydioxanone interrupted sutures with the knots tied anteriorly to prevent

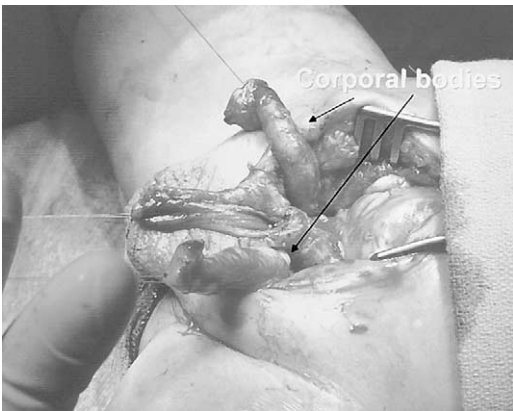

Fig. 7. Penile disassembly is performed sharply to separate the corporal bodies from each other. The corporal bodies do not have a shared blood supply.

suture erosion into the bladder neck (Fig. 10). Rectus fascia is re-approximated using a running 2.0 polydioxanone suture. Penile shaft skin is reconfigured using either a primary dorsal closure or reversed Byar’s flaps (if needed) to provide dorsal skin coverage. Skin covering the abdominal wall is re-approximated using a two-layer running closure of absorbable monofilament sutures.

Occasionally, significant discrepancies in the dorsal and ventral lengths of the corpora will require dermal graft insertion. However, this is rarely needed in the newborn closure. The corpora are re-approximated with fine, interrupted sutures along their dorsal aspect.

The urethra can then be brought up to each hemiglans ventrally to create an orthotopic meatus (Fig. 11). The glans is reconfigured using interrupted mattress sutures of polydioxanone suture (ie, PDS®) followed by horizontal mattress sutures of 7.0 monofilament suture (ie, Maxxon®) to re-approximate the glans epithelium. The neourethra is matured with 7.0 braided polyglactin suture (ie, Vicryl®). The authors also perform glans tissue reduction to create a conical appearing glans.

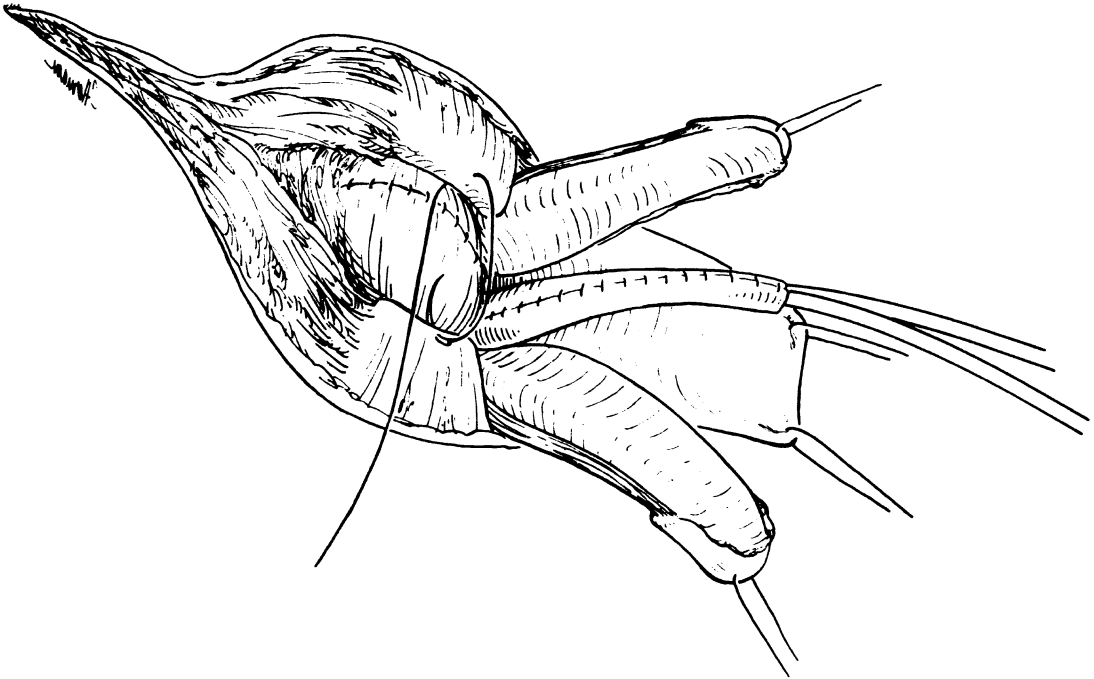


Fig. 8. Urethral tubularization in continuity with bladder neck closure. If the bladder neck is not patulous, no specific effort at bladder neck reconstruction is made at the time of closure.

Success rates

Cosmesis

Reported rates of success for epispadias repairs vary. The degree of epispadias, the age of the

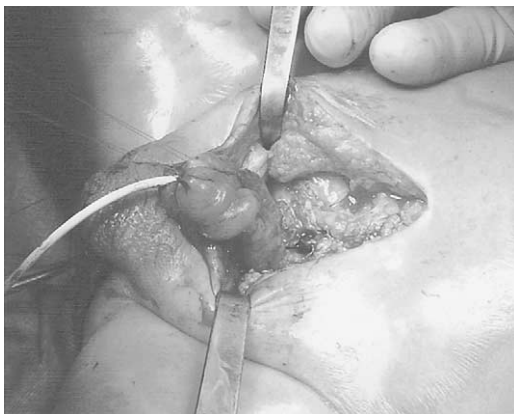

Fig. 9. The corporal bodies will rotate medially. This helps to correct the chordee and also moves the neurovascular bundles to a more normal anatomic relationship distally.

patient, surgeon experience, and the presence of previously operated tissues all impact the successful outcome of epispadias repair. Furthermore, penile cosmesis is a subjective measurement. A satisfactory appearance to the surgeon may not equal that of the patient's expectations and vice-versa. The cosmetic success rates of reported series are thus difficult to validate and compare for this repair. A recent review of the Cantwell–Ransley technique in 40 patients reported a successful anatomic and functional result in 90% of the patients at a mean follow-up period of 3 years [12]. Zaontz and colleagues reported on a multi-center experience using the total penile disassembly technique and found that 16 of 17 boys had straight erections following repair [13]. Perovic has described variants of the disassembly technique for epispadias that may be used in selected circumstances as well [14].

Continence

Continence rates following male epispadias repair using the complete penile disassembly technique approach 80% (volitional voiding with continence intervals ≥ 3 hours) [9]. For patients who

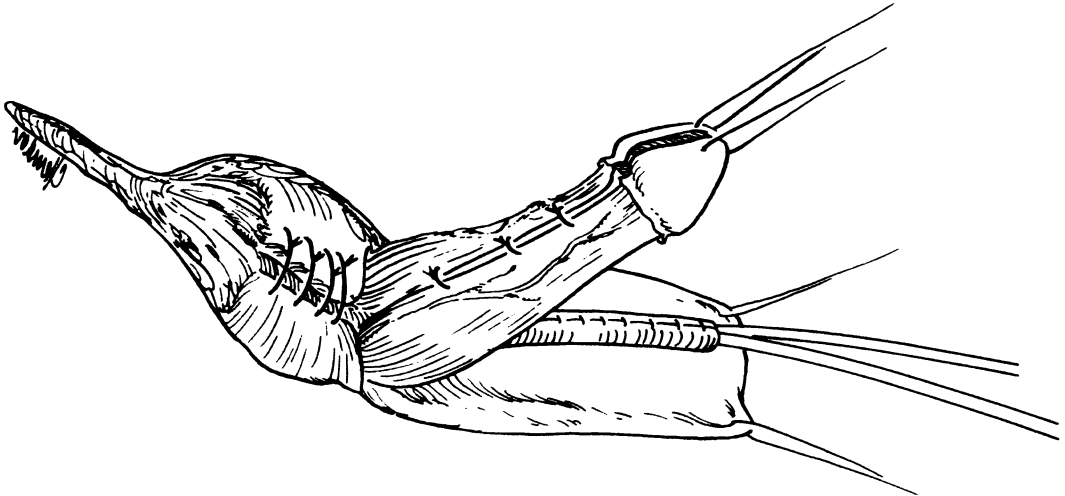


Fig. 10. The pubis symphysis is re-approximated after the urethra and bladder neck have moved posteriorly underneath the corporal bodies.

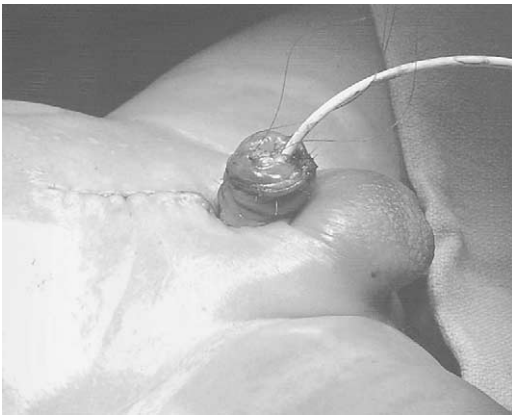


Fig. 11. The urethra typically possesses enough length to reach the glans. Penile skin coverage may be provided by reversed Byar's flaps.

do not gain sufficient urinary continence following the primary repair the authors have been able to achieve urinary continence using a modification of the Ledbetter bladder neck procedure.

Complications

Complications of epispadias repair include the development of urethrocutaneous fistulas, persistent chordee, difficulty with urethral catheterization, and erectile dysfunction. Fistulas typically occur dorsally at the base of the penis. This is the area where tissue coverage is most tenuous and the corporal bodies do not yet cover

the reconstructed urethra. Fistula rates for the Cantwell–Ransley repair range from 5% to 20% [15,16]. Fistula rates using the total penile disassembly technique are 10% to 20% [11,13,14].

Lottman and colleagues reported complications that required further surgical reconstruction in 45% of their patients who underwent a modified Cantwell–Ransley repair. Complications were more common in patients who underwent this procedure as part of a staged exstrophy closure versus isolated epispadias [12]. The high rate of re-operation reflects the technical difficulty involved in epispadias repair, even in experienced hands.

Although both the Cantwell–Ransley and total penile disassembly techniques can be employed as salvage procedures for the older child, these patients may also require dorsal dermal grafts to achieve a straight penis. The neurovascular bundles may also require mobilization to allow graft placement in this situation. Otherwise, it is more prudent to avoid excessive mobilization and handling of these nerve bundles when possible.

Finally, the popularization of the Mitrofanoff principle has significantly improved the management of those patients with tortuous neourethras following urethral reconstruction. Incidentally, this has not been a problem with the complete penile disassembly technique. Creation of a Mitrofanoff channel allows patients who require intermittent catheterization of their bladders to do so easily. Most patients with bladder exstrophy

that require clean intermittent catheterization (CIC) prefer to do so through a Mitrofanoff rather than per urethra even if urethral catheterization is technically straightforward. Patients repaired using the CPD technique rarely require catheterization, however. The authors do not expect that patients with epispadias who have been repaired with the complete penile disassembly technique will require CIC.

Female epispadias

Female epispadias occurs more rarely than male epispadias, at approximately 1/150,000 to 1/300,000 live female births. As a consequence, even at large tertiary care centers, experience with the management and treatment of this anomaly is limited. Most series in the literature report on <15 patients [17–19].

The condition may be missed during the newborn examination and only recognized later when the affected child presents with severe urinary incontinence. This is unfortunate, because early repair may result in early bladder cycling and increase the potential for later urinary continence with voiding. Typically, the sphincteric mechanism is compromised in girls with epispadias, resulting in stress urinary incontinence that may be near total. Occasionally, these children are incorrectly diagnosed as intersexed; in deJong's series, three of four girls were initially misdiagnosed with an intersex condition [17].

As in the case for boys with epispadias, the optimal surgical approach returns the altered anatomy to as normal an anatomic location as possible. Specific goals in the management of these patients include:

- Creation of a straight urethra
- Satisfactory cosmesis with symmetric re-approximation of genitalia in the midline
- Minimal complications
- Creation of urinary continence
- Maintenance of clitoral function

Because urinary continence invariably affects these patients, traditional surgical approaches have relied on a staged technique adapted from those used for boys with penopubic epispadias [18].

The first stage involves urethral and vulvar reconstruction. During the second stage, the child undergoes bladder neck reconstruction to increase outlet resistance. Timing for these stages can vary, but the second stage is usually deferred until the child expresses an interest in toilet training.

More recently, one-stage techniques have been described. Grady and Mitchell have applied the complete primary repair technique used for exstrophy to female epispadias [20]. DeJong and co-workers have also described a technique that relies on similar principles but also utilizes a concomitant modified needle bladder neck suspension technique [17]. With these one-stage techniques the key principle involves extensive mobilization of the urethra and bladder neck with the vagina as a unit so that these structures can be moved posteriorly into a more anatomically normal intra-abdominal position. As a result, these patients have the potential to gain urinary continence without the need for bladder neck reconstruction.

Patients and their families should be counseled about the possible need for short-term or life-long CIC following epispadias repair aimed at achieving urinary continence. If patients or their families are reluctant to perform CIC per the urethra, the operations should be delayed or alternatives such as the creation of a Mitrofanoff channel for CIC should be considered.

Complete primary epispadias repair technique: female epispadias

The principles of this single-stage technique are the same in boys and girls. After preoperative antibiotic therapy is given and the patient is prepared and draped in a sterile field, the authors mark the planned lines of incision (Fig. 12). The bladder neck, urethra, and vagina are mobilized as a unit. The authors perform this dissection with tungsten-tip electrocautery (Colorado[®] tip) to minimize tissue damage while achieving hemostasis. The plane of dissection occurs anteriorly along the medial aspect of the bifid clitoris and proceeds posteriorly along the lateral aspect of the vaginal vault (Fig. 13). The vagina is mobilized with the urethra and bladder neck. The urethra and bladder neck should not be dissected from the anterior vaginal wall because this will compromise the blood supply to the urethra. During the posterior lateral dissection the intersymphyseal bands will be encountered and should be deeply incised to allow the urethra and bladder neck to move posteriorly. The posterior limit of the dissection is reached when the pelvic floor musculature is exposed.

Following adequate dissection, the vagina, urethra, and bladder neck are moved posteriorly in a Y–V plasty fashion (Fig. 14). The urethra is then tubularized using a two-layer closure of

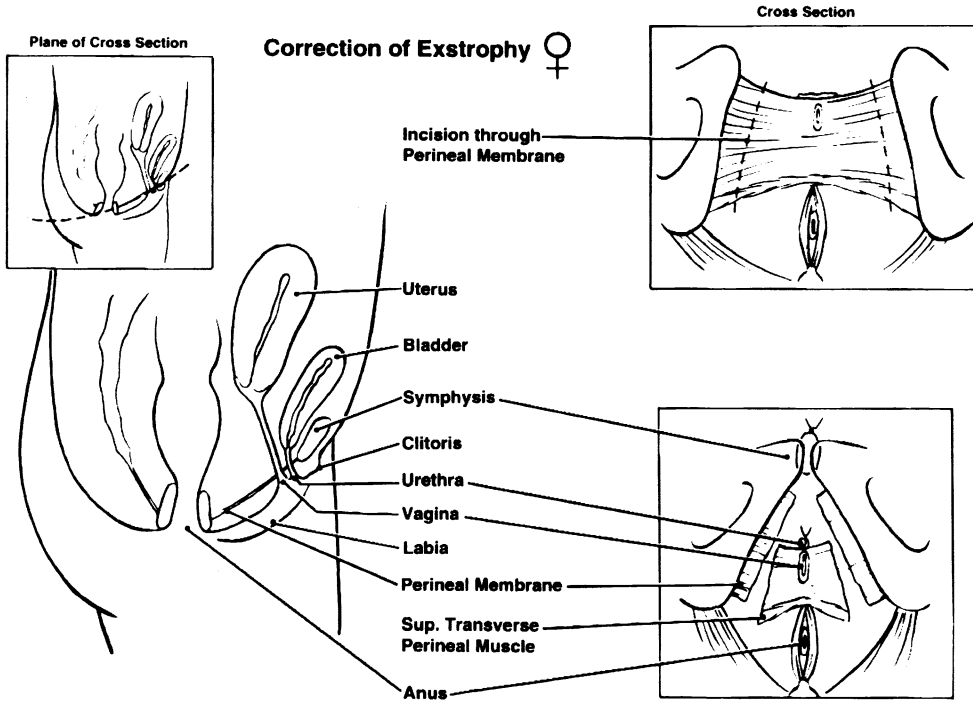


Fig. 12. Schematic diagram of lines of incision for complete primary repair of a female infant with bladder exstrophy. Note how this concept has been applied to the repair of female epispadias in Fig. 13 demonstrating lines of incision for an infant girl with epispadias. Note the posterior extent of dissection to allow movement of the vagina, bladder neck, and urethra as a unit posteriorly.

absorbable sutures. Prior to the urethral closure the authors routinely place a suprapubic tube to assist with post-operative management. The pubis symphysis is re-approximated using 0.0 PDS

suture (Fig. 15). Osteotomies may be necessary when a wide pubic diastasis prevents a low-tension re-approximation of the pubic symphysis. The authors use anterior iliac osteotomies in these situations. The rectus fascia can then be closed in the midline. The authors mature the neourethra

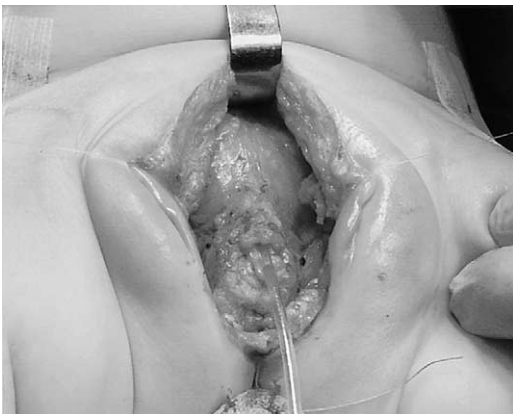

Fig. 13. The plane of dissection lies adjacent to the urethra and vaginal vault and must be carried through the intersymphyseal band on both sides. The clear catheter is placed through the bladder neck.

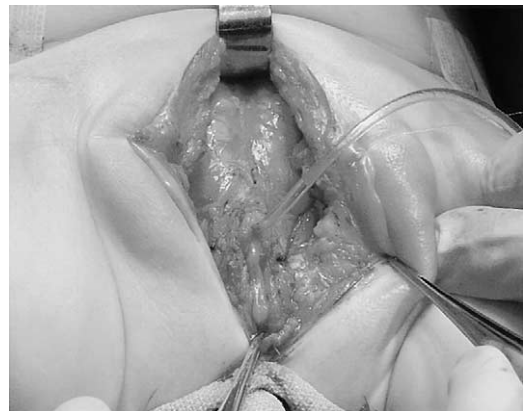


Fig. 14. The urethra is tubularized and the vagina, urethra, and bladder neck are moved posteriorly.

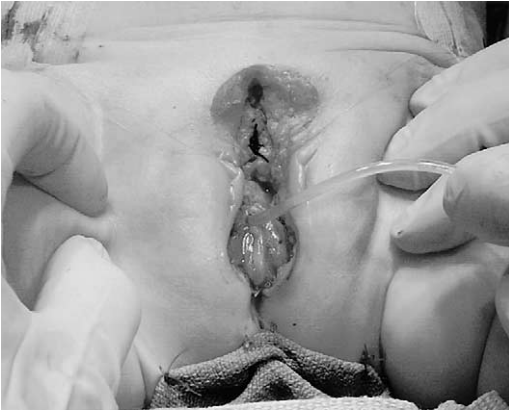

Fig. 15. The pubis symphysis is re-approximated. With adequate dissection, the pubis symphysis can be re-approximated with minimal compressive effects on the urethra and bladder.

with 5.0 Vicryl® sutures and re-approximate the bifid clitoris by denuding them medially so that they fuse together after suturing with 7.0 Maxxon® sutures (Fig. 16). If needed, the labia majora may be advanced posteriorly to the perineum at this time as well (Fig. 17).

The authors maintain these patients on suppressive antibiotic therapy post-operatively while indwelling catheters are in place. Anticholinergic therapy is also used to treat post-operative bladder spasms. The authors also use a Spica cast to decrease lateral stresses on the closure in the post-operative period.

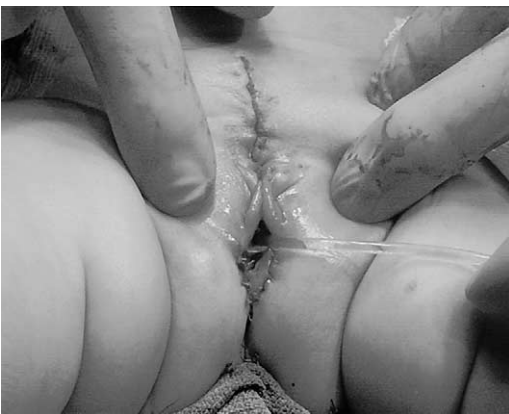

Fig. 16. Final reconstruction demonstrates apposition of the labia and clitoral bodies. Denuding the epithelium on the clitoris medially improves the cosmetic results post-operatively.

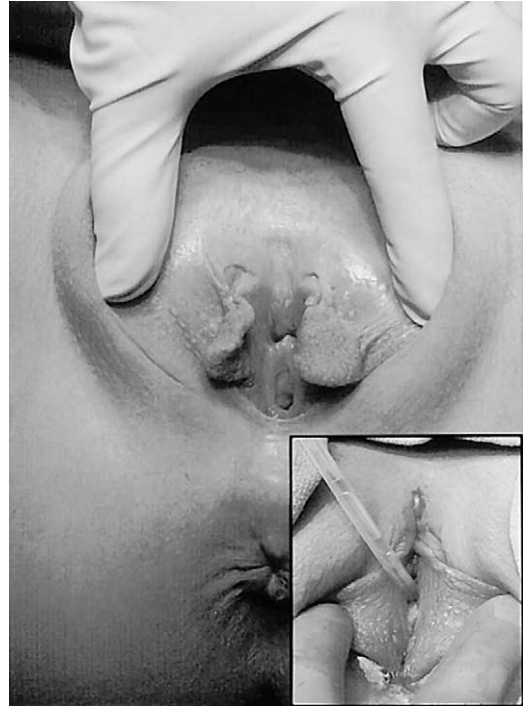


Fig. 17. Pre- and Post-operative appearance of a 16-year-old girl with epispadias. The labial incisions have been carried posteriorly to allow the posterior aspect of the labia to reach the perineal body. This improves the cosmetic appearance of the external genitalia.

Success rates

No reported series is large enough to make definitive statements about rates of satisfactory cosmesis or continence. The small series reported in the literature have continence rates ranging from 50% to 87.5% [17,18,21]. With his one-stage technique deJong reported a continence rate of 3 of 3 patients. One required CIC to empty her bladder and one had some degree of stress urinary continence with sports activity, however. Two of these patients were also treated with endoscopic periurethral injection of silicone granules [17].

Conclusions

Epispadias represents one end of the spectrum of the exstrophy–epispadias complex. As a result, the lessons the authors have learned from the management of bladder exstrophy may be applied to the management of epispadias. Because epispadias is rare and the operative techniques are technically challenging, it is important to involve a surgeon who is experienced in the care of these

patients. A long-term commitment to these patients is also necessary. As evidenced by the success rates at even the most experienced centers, some patients will require further operations to achieve urinary control, and many will require more conservative measures to optimize urinary continence, body image, and sexual function. The promise of one-stage techniques to simplify the operative management of these patients represents a significant advance in the care of epispadias.

References

- [1] Woodhouse CR, Kellett MJ. Anatomy of the penis and its deformities in exstrophy and epispadias. *J Urol* 1984;132:1122–4.
- [2] Hamper UM, et al. Bladder exstrophy–epispadias complex: prostatic evaluation by transrectal ultrasonography. *Prostate* 1991;19:133–40.
- [3] Gearhart JP, et al. Prostate size and configuration in adults with bladder exstrophy. *J Urol* 1993;149:308–10.
- [4] Avolio L, et al. The long-term outcome in men with exstrophy/epispadias: sexual function and social integration. *J Urol* 1996;156:822–5.
- [5] Ben-Chaim J, et al. Bladder exstrophy from childhood into adult life. *J R Soc Med* 1996;89:39P–46P.
- [6] Lattimer JK, et al. Long-term followup after exstrophy closure: late improvement and good quality of life. *J Urol* 1978;119:664–6.
- [7] Woodhouse CR, Ransley PG, Williams DI. The patient with exstrophy in adult life. *Br J Urol* 1983;55:632–5.
- [8] Cantwell F. Operative technique of epispadias by transplantation of the urethra. *Ann Surg* 1895;22:689–95.
- [9] Grady RW, Mitchell ME. Complete primary repair of exstrophy [see comments]. *J Urol* 1999;162:1415–20.
- [10] Gearhart JP, et al. The Cantwell–Ransley technique for repair of epispadias. *J Urol* 1992;148:851–4.
- [11] Mitchell ME, Bagli DJ. Complete penile disassembly for epispadias repair: the Mitchell technique. *J Urol* 1996;155:300–4.
- [12] Lottmann HB, Yaquouti M, Melin Y. Male epispadias repair: surgical and functional results with the Cantwell–Ransley procedure in 40 patients. *J Urol* 1999;162:1176–80.
- [13] Zaontz MR, et al. Multicenter experience with the Mitchell technique for epispadias repair [see comments]. *J Urol* 1998;160:172–6.
- [14] Perovic SV, et al. Penile disassembly technique for epispadias repair: variants of technique. *J Urol* 1999;162:1181–4.
- [15] Lottmann HB, Yaquouti M, Melin Y. Male epispadias repair: surgical and functional results with the Cantwell–Ransley procedure in 40 patients. *J Urol* 1999;162:1176–80.
- [16] Surer I, et al. The modified Cantwell–Ransley repair for exstrophy and epispadias: 10-year experience. *J Urol* 2000;164:1040–2, discussion 1042–3.
- [17] de Jong TP, Dik P, Klijn AJ. Female epispadias repair: a new 1-stage technique. *J Urol* 2000;164:492–4.
- [18] Gearhart JP, Peppas DS, Jeffs RD. Complete genitourinary reconstruction in female epispadias. *J Urol* 1993;149:1110–3.
- [19] Kramer SA, Kelalis PP. Surgical correction of female epispadias. *Eur Urol* 1982;8:321–4.
- [20] Grady RW, Mitchell ME. Complete primary repair for epispadias. In: Seattle, WA: Northwest Urological Society; 2001.
- [21] Hendren WH. Congenital female epispadias with incontinence. *J Urol* 1981;125:558–64.